2} Abdominal Examination (Abdominal Grips)

Goal:

This activity will increase nursing skills, knowledge and confidence of the student nurse in performing abdominal examination to pregnant woman.

Objectives:

By the end of this procedure, the student nurse should be able to:

- Prepare the appropriate equipment needed for doing abdominal examination of pregnant woman.
- List the indication and contraindication of abdominal examination.
- Demonstrate Leopold maneuvers.

Outlines:

1. Introduction
2. Definition
3. Purposes
4. Indications
5. Contraindication
6. Techniques of abdominal examination.

Introduction:

Local abdominal examination is done for the pregnant woman, which contains inspection and palpation of the pregnant woman's abdomen to determine the duration of pregnancy, lie, attitude and the position of the fetus. Abdominal examination provides the pregnant woman with assurances that her pregnancy is progressing well.

Definition:

Examination of a pregnant woman to determine the normalcy of fetal growth in relation to the gestational age ,position of fetus in uterus and its relationship to the maternal pelvis.

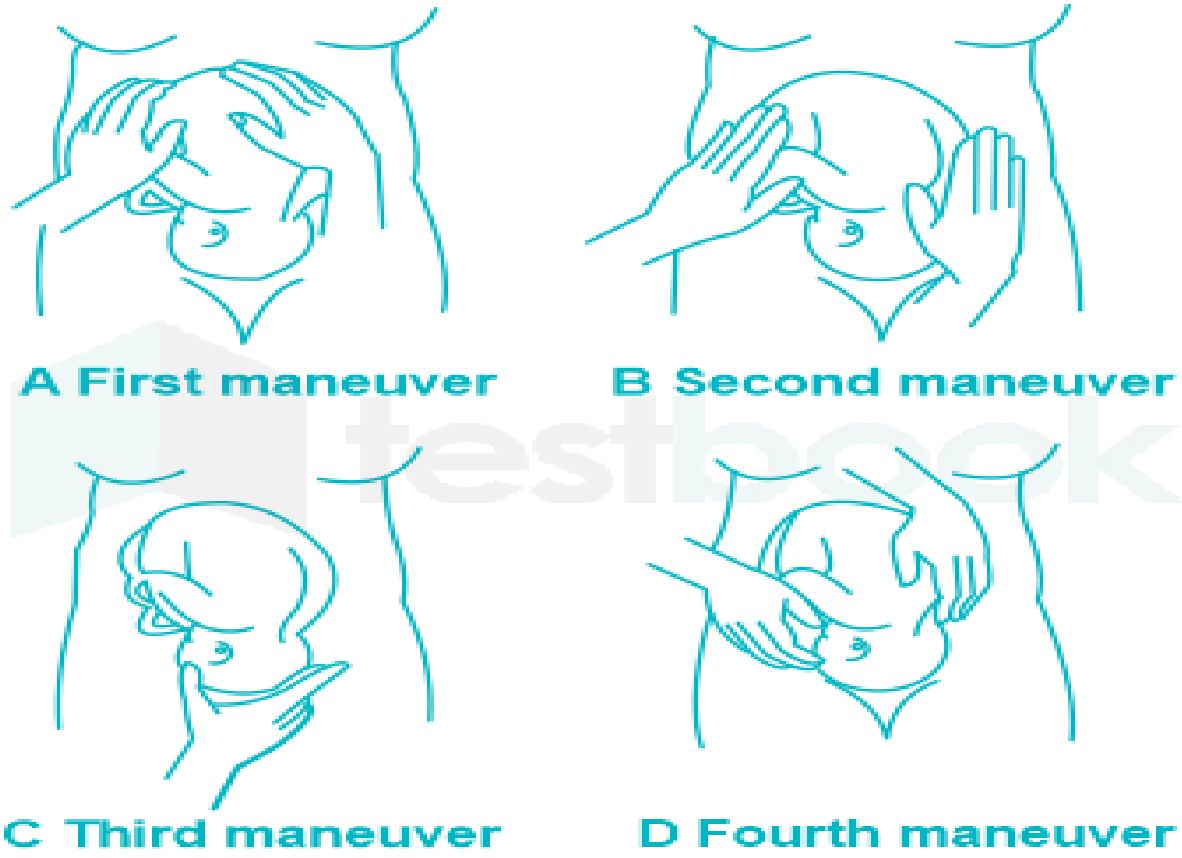

Time: -

Leopold maneuver is performed late in pregnancy after the uterus becomes large enough to allow differentiation of fetal parts by palpation.

Purposes:

- To estimate the period of gestation.
- To determine presentation, lie, position, and engagement of the presenting part.
- To assess fetal well-being by checking fetal movement and fetal heart sounds.
- To detect any deviation from the normal.
- Assess fetal growth and size.

Indications:

- Each antenatal assessment.
- On admission to hospital (for any reason)
- Generally, daily in hospital.
- Prior to invasive treatment (amniocentesis).

Contraindication:

- Placenta abruption.
- Premature labor
- Prior to auscultation of the FHR.

Equipment:

1. Tap measure.
2. Pinard fetoscope or sonic fetal heart sound device.
3. Client record.

2} Abdominal Examination Learning Guide

Action	Rational
Getting Ready	
1. Prepare the necessary equipment: pinard or sonic fetal heart sound device and gloves.	
2. Wash hands and dry.	To prevent spread of infection.
3. Stand on the right side of the mother.	
4. Greet the mother respectfully and with kindness, introduce yourself.	
5. Explain the procedure and obtain the woman's agreement, encourage her to ask questions, and listen to her.	
6. Instruct the woman to empty bladder.	☞ Promote comfort and accuracy of evaluation ☞ Full bladder will displace the uterus and cause wrong fundal height reading.
7. Position the woman on the examination couch on her back	☞ To relax the abdominal muscles.

with her knees flexed and slightly separated	
8. Put a pillow under her head and put her arms down to her side.	☞ To avoid supine hypotensive syndrome, if using the right hand.
9. Keep the woman's privacy. Provide her with a drape or cloth to cover the parts of her body that are not being examined and uncover her abdomen.	
10. Warm hands if cold by rubbing them together.	
11. Inspect the abdomen for: - **a. Size:** large or small. **b. Shape**: pendulous abdomen in a primigravida suggested contracted pelvis. **c. Scares of previous operation**: as caesarean section scare. **d.** Pigmentation as linea nigra. **e. Striae gravidarum**. **f. The hair distribution.** **g. Edema & the presence of hernia.**	☞ If abnormally huge it suggests multiple pregnancy or polyhydramnios. ☞ Suprapubic hair (feminine with an upper straight border, or masculine with a convex upper border, which suggests android pelvis
11- Palpate the abdomen:	

1- Fundal level:

- To determine the gestational age.

Technique: Place the ulnar border of the left hand just below the xiphisternum and move it down the abdomen until the fundus is felt. Measure the number of fingers that can fit between the upper border of umbilicus to the fundus (Upper border of umbilicus equal 24 weeks & each one finger above upper border equal one week).

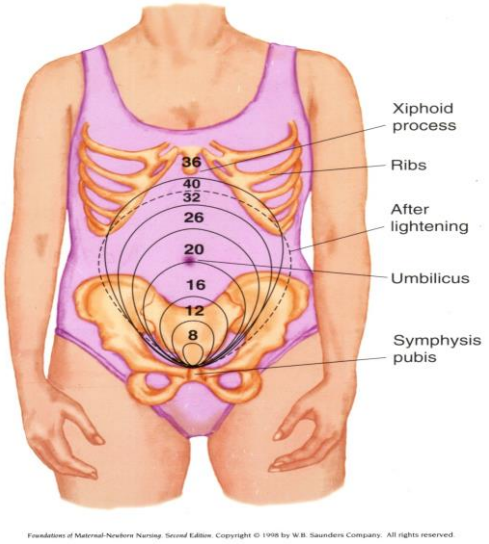

At 36 weeks, the fundus height will be at the level xiphesternum. At 40 weeks. It will be 3 – 4 fingers below the xiphesternum.

2- First Maneuver (Fundal Grip):

- To determine which part of the fetus occupied the fundus

☞ . **Technique:** Hands are moved up the side of the uterus and the fundus is replaced. In most

cases, the buttock is felt and it is softer, more irregular, less globular and less mobile than the head.

Findings:

1. Fetal head feels round and hard in the fundus, is readily movable and can be balloted between the thumb and a finger of one hand. That indicate longitudinal lie.

2. Fetal buttock in the fundus, feels irregular, large, fewer firms than head. It cannot be well delineated, readily moved, or balloted that indicate longitudinal lie.

Neither of the above is felt in the fundus, that indicate transverse lie.

3-Second Maneuver (Bilateral Grip):

To determine the position of fetal extremities, the fetal back, and fetal anterior shoulder.

☞ **Technique:** Hands are placed on the sides of the abdomen to

identify the location of the back and small parts.

Findings:

1. A firm, convex, continuously smooth and resistant mass extends from the buttock to the neck is indicative of the fetal back.

N.B: The location of the back on the left side or right side of the women's abdomen indicates the position in longitudinal lie.

2. Small knobby, irregular masses, may move when pressed on or may kick or hit the examiner's hand is indicative of the fetal small parts (e.g. hands, feet, knees, elbow) they should be on the opposite side of the women than the fetal back.

3. The head or buttock is palpated on either side instead of in the funds or at the symphysis pubis is indicative of the transverse or oblique lie.

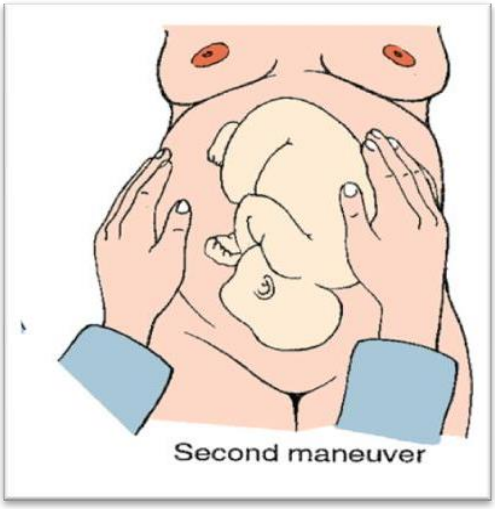

4- Third Maneuver (The paw lick grip or 1st pelvic grip or first pelvic grip):

To determine if the presenting part engaged or not.

Technique: the lower uterine segment (above the symphysis pubis) is grasped between the thumb and fingers of one hand to feel the presenting part. The head is at the inlet or in the pelvis in 90% of cases.

Finding:

1. In case that the presenting part is the head and it is not movable, the engagement is occurred but if it is movable, the engagement is not occurred.

NB: In case of cephalic presentation or breech presentation, the fetal lie is longitudinal. Neither of the above is palpated, the fetal lie is transverse.

Third maneuver

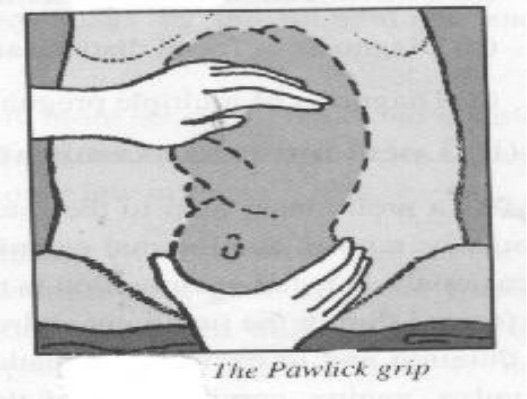

The Pawlick grip

5-Fourth Maneuver (2nd pelvic grip):-

To confirm the findings of the third maneuver and to determine the flexion of the vertex.

Technique: The examiner turns and faces the mother's feet then; gently the fingers are moved down the sides of the uterus toward the pubis. The cephalic prominence is felt on the side where there is greater resistance to the decent of fingers into the pelvis.

Findings:-

a. If the attitude is flexion, the forehead is the cephalic prominence and it is on the opposite side to the back.
b. If the attitude is extension, the occiput is the cephalic prominence and it is on the same side as the back.
c. If the attitude is military, the examiner cannot feel any prominence on the two sides or feel prominence on the two sides.

6. **Auscultation of Fetal Heart Sounds** "Listening to fetal heart sounds" The fetal heart is most easily heard by listening over the back of the fetus (anterior shoulder). Therefore the lie and position of the fetus must be established by palpation before listening for fetal heart. The fetal heart can be auscultated using a fetal stethoscope (pinard or sonic fetal heart sound device). If you are using a fetal stethoscope "Pinard ☞ Stethoscope", places the opening of the cone vertically on the abdomen as in the previous step and place good ear on the other end of the stethoscope. ☞ Take hand off the stethoscope so that it is only held in place by head. ☞ Move head slowly in a circular manner until hear the fetal heart.	

☞ Listen to fetal heart for a full minute, counting beats against the seconds' hand of watch to determine the heart rate	
Post Procedure Tasks	
12. Drape the exposed abdomen.	
13. Help the women to get down from the examination table.	
14. Record finding and woman's reaction to the examination.	
15. Replace equipment.	
16. Wash hands.	

Abdominal Examination Checklist

Action	First Trial		Second Trial	
	Done	Note Done	Done	Note Done
1. Prepare the necessary equipment.				
2. Wash hands, warm it if cold by rubbing them together				
3. Welcome to the woman, introduce myself, and explain procedure.				
4. Take woman's agreement to doing procedure				
5. Instruct the woman to empty bladder before examination.				
6. Keep privacy.				
7. Assist woman to lie in supine position with one pillow under her head and her knees slightly flexed and separated.				
8. Expose the woman's abdomen from symphysis pubic to xiphoid, leaving legs and pubic area covered.				
9. Place small rolled towel under woman's right hip.				
10. Stand on woman's right and facing her.				
11. Inspect the abdomen for size, shape, skin pigmentation.				

12. Palpate the abdomen				
A-Fundal level: This gives idea about the duration of pregnancy. a) Stand on the right side of the woman. b) Palpate with warm hands. c) Push the uterus centrally by the palm of the right hand. d) The ulnar border of the left hand is moved from the xiphoid cartilage downwards until the resistance of the fundus is felt. e) Measure the number of fingers, which can fit between the fundus and xiphesternum, or measure the distance from the symphysis pubis to the fundus using a tap measure.				
B- Fundal grip or (1st maneuver): - a) Still on the right side of the woman and looking to her face. b) The fundus of the uterus is palpated with both hands. c) To determine which parts of the fetus lying in the fundus of the uterus (head or breach). d) To determine the lie of the fetus				

weather longitudinal or transverse.				
C- The lateral or umbilical grip (2nd maneuver): - a) Remain facing the woman head. b) Place the palms of hands on both sides of the abdomen at the level of the umbilicus. c) Steady the uterus with hand on one side and palpate the opposite side (this is done alternately). d) To determine the location of the fetal back & limbs (which part of the fetus occupying the side wall of the uterus.				
D- The pawlick grip or 1st pelvic grip (3rd maneuver): - a) Still standing on the woman's right side & facing her. b) The right hand is placed on the symphysis pubis with the thumb parallel to the right inguinal ligament and the four fingers parallel to the lift ligament, the other hand is placed by the side of the uterus to fell the trunk of the fetus, and ask the woman to take a deep breath and let it out. c) As she exhale approximate thumb and				

fingers together to feel the part of the fetus occupying the lower uterine segment. d) This grip shows the presenting part (head or breech), its size, mobility and the degree of decent in the pelvis.				
The 2nd pelvic grip (4th maneuver): - a) Face the woman's feet. b) The two hands are placed on the lower part of the uterus. c) Gently move the tips of your fingers down the sides of the abdomen towards the pelvic brim and approximated at the same time. d) This grips helped to determine: • The nature of that part occupying the lower uterine segment. • Whether the presenting part is floating, fixed or engaged. • The position and flexion of the presenting part.				
12- Auscultation:				
Auscultate the abdomen to listen to the fetal heart sound.				
13- Drape the exposed abdomen.				
14- Record findings and woman's reaction to				

the examination.				
15- Replace equipment				
16- Wash hands.				
Procedure score				
Date				

Student name: **Instructor name:**